

## Rationale of salvage procedures for failed resection arthroplasties of the distal radio-ulnar joint

P Hernández-Cortés\*, R Gómez-Sánchez, M Pajares-López

### Abstract

#### Introduction

Radio-ulnar joint impingement appears to be inevitable after distal ulna resection arthroplasties. It is a cause of pain and disability in many patients and sometimes requires revision surgery.

The objectives of this review were to describe reported procedures for revision surgery after failed resection arthroplasty of the distal radio-ulnar joint, to critically evaluate the indications for these procedures and to investigate their functional outcomes and complications.

#### Method

An Internet search of the MEDLINE and EMBASE databases revealed a weak level of scientific evidence, with no randomized controlled trials comparing different operative managements and no prospective case series. This review is limited to data from retrospective studies and case reports.

#### Conclusion

Distal tenodesis is ineffective. Placement of a partial or total distal radio-ulnar joint prosthesis is the sole option for re-establishing the distal pivot point necessary for adequate tensioning of the interosseous membrane and for restoring the optimal transfer of loads from radius to ulna and vice versa. However, concerns have been raised about the utilization of these procedures in young and in high-demand patients. Allograft

tendon interposition is an alternative to prosthesis substitution.

#### Introduction

When a distal radio-ulnar joint (DRUJ) causes refractory pain and there is extensive damage to the joint cartilage, the only available surgical option is to sacrifice the joint by complete resection of the distal ulna (popularized by Darrach), by partial resection with or without interposition (e.g. Bowers' hemiresection or Watson's 'matched ulna') or by fusion of the radius and distal ulna with proximal pseudoarthrosis [Sauvé-Kapandji (S-K) procedure].

These options, especially Darrach's resection, have been widely used, and the satisfactory pain and mobility outcomes achieved (>80%) have long been documented<sup>1</sup>.

However, it is increasingly acknowledged that these arthroplasties can fail, with patients reporting pain and weakness in grip and object lifting, and even clunking with pronosupination due to instability of the distal forearm<sup>2,3</sup>. This instability takes place in the anteroposterior plane, with X-rays showing radio-ulnar convergence and wear in the medial cortex of the radius at the ulnar stump end<sup>4</sup> (Figure 1). This complication is reported as radio-ulnar impingement syndrome<sup>2</sup> or convergent instability of the distal ulnar stump<sup>5</sup>, and various dynamic radiographic studies have used different methods to determine its frequency and the influence of distinct procedures or techniques on this loss of stability.

Since the introduction of a novel radiographic view by Lees and Scheker in 1997<sup>6</sup>, radiographic radio-ulnar convergence has been observed in

100% of cases and affects patients equally after Darrach's resection, S-K procedure, or partial resection (Figure 2). One explanation that has received little attention is that DRUJ is a load joint and critical for lifting objects. When a weight is held in the hand with the elbow flexed and forearm in neutral rotation, the radius is centred on the ulnar head, producing a transverse load and exerting a compressive force<sup>7</sup>.

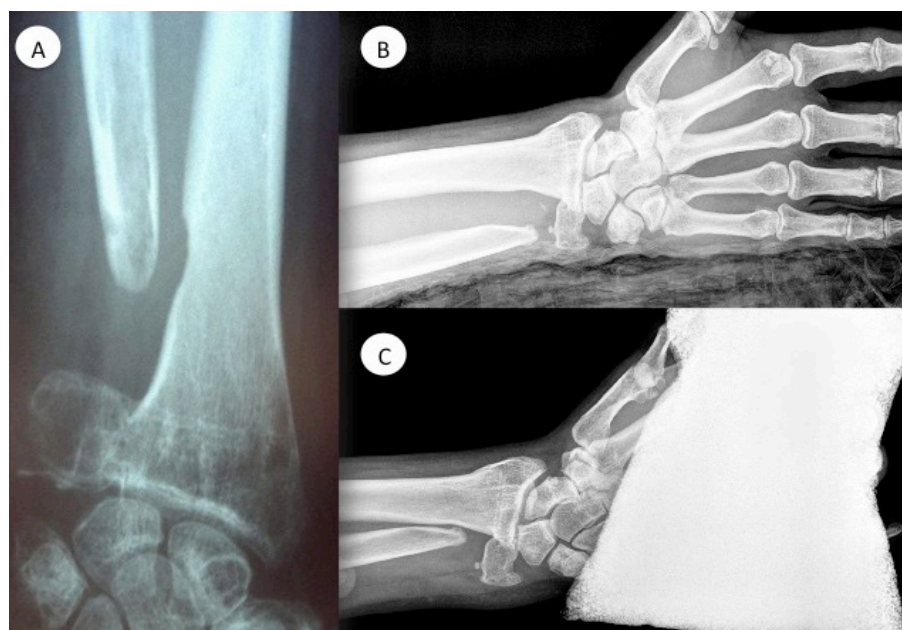
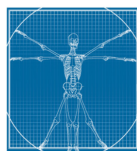
Moreover, the contraction of the muscles connecting the ulna and radius favours convergence once these bones are free of contact with the ulnar head. García-Elias demonstrated the role of the anterior brachial muscle, pronator quadratus and long abductor muscle of the thumb in this phenomenon<sup>8</sup> (Figure 3), whereas other authors highlighted the role of the short thumb extensor and the flexor digitorum profundus of the second and third fingers.

The percentage of distal ulna resections with symptoms of radio-ulnar impingement ranges between 8% and 50%, depending on the series. Although no association has been established with any specific radiographic parameter, an excessively high ulnar osteotomy appears to have a negative effect<sup>9</sup>. It has been claimed that the ulnar stump meets an area of the radius that is unfavourable for contact<sup>8</sup>, but we believe that there may be more important biomechanical causes of this complication.

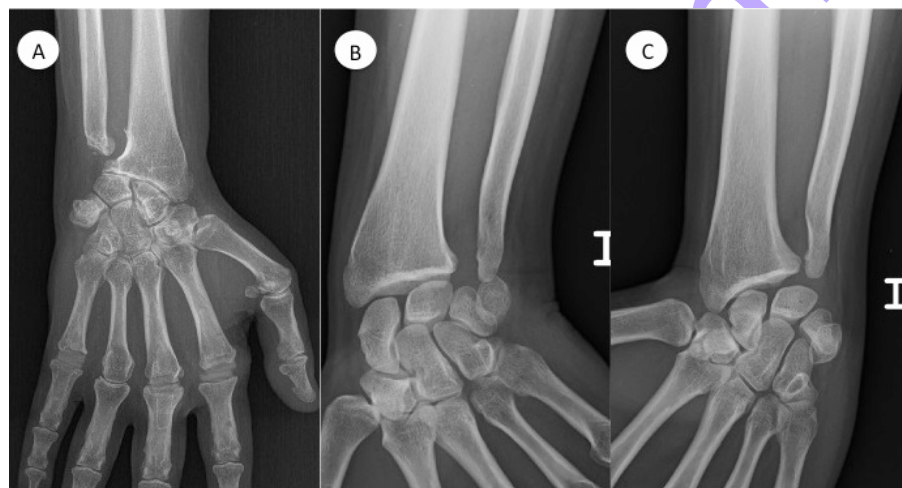
In DRUJ surgery, the instability of the distal ulna can be reduced by preserving soft tissue stabilizers such as the triangular fibrocartilage complex (TFCC) and radio-ulnar ligaments, posterior ulnar tendon sheath, interosseous membrane and

\* Corresponding author  
Email: hdezcp@hotmail.com

Hand Surgery Unit, Orthopedic Surgery  
Department of 'San Cecilio' University  
Hospital of Granada, Spain



**Figure 1:** (a) Radio-ulnar impingement in Sauvé-Kapandji procedure. X-ray shows radio-ulnar convergence and wear in the medial cortex of the radius at the ulnar stump end. (b) Antero-posterior projection of wrist with Sauvé-Kapandji, with the elbow at 90° flexion and intermediate pronosupination. (c) Scheker's radiographic view: in the position reported in (b), the patient holds a weight of 2.2 kg, and radio-ulnar impingement is observed.



**Figure 2:** Radio-ulnar impingement in Darrach's arthroplasty and partial ulna resection. (a) Darrach procedure in a rheumatic patient, showing exostosis on the ulnar stump and wear of the contact area on the radius. (b and c) Bowers' hemiresection and dynamic radiographic study evidencing radio-ulnar convergence in (c).

pronator quadratus muscle<sup>10</sup>. However, none of these structures offer protection against convergence (Figure 4).

Radio-ulnar impingement appears to be inevitable, but the onset of

symptoms is unpredictable and depends more on the physical demands of the patient than on variations in DRUJ resection techniques.

The objectives of this review were to outline published procedures for

revision surgery after failed resection arthroplasty of the DRUJ, to critically evaluate the indications for these procedures and to investigate their functional outcomes and complications.

### Methods

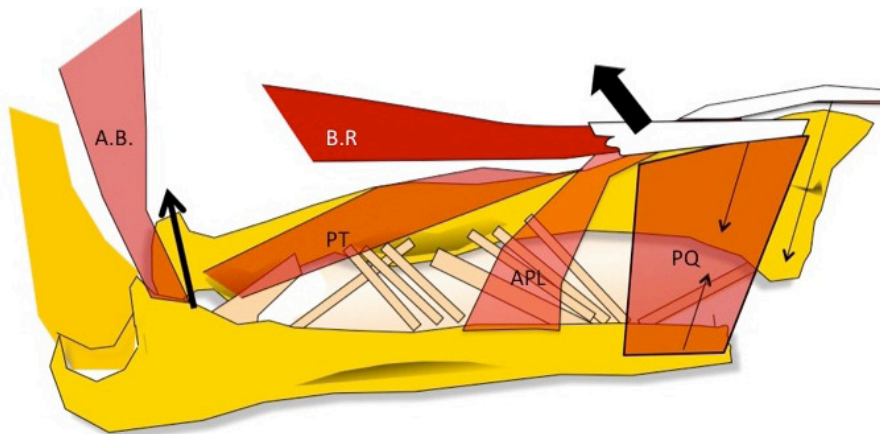
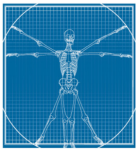An Internet search of MEDLINE and EMBASE databases was performed on 11 February 2013, using the search terms: 'Failed Darrach procedure', 'Failed Sauvé-Kapandji procedure', 'Failed Bower's hemiresection procedure', 'Failed matched ulna arthroplasty', 'Failed distal ulna resection', 'Salvage of failed DRUJ resection', 'Radio-ulnar impingement syndrome', 'Treatment of radio-ulnar impingement', 'Stabilization of ulnar stump' and 'Salvage procedure for distal end of the ulna'. The reference lists in all relevant identified papers were also screened to identify other studies for inclusion in this review. Letters to the Editor, purely radiological studies and articles on DRUJ primary surgery or the non-surgical management of failed DRUJ arthroplasty were excluded from this review.

### Results

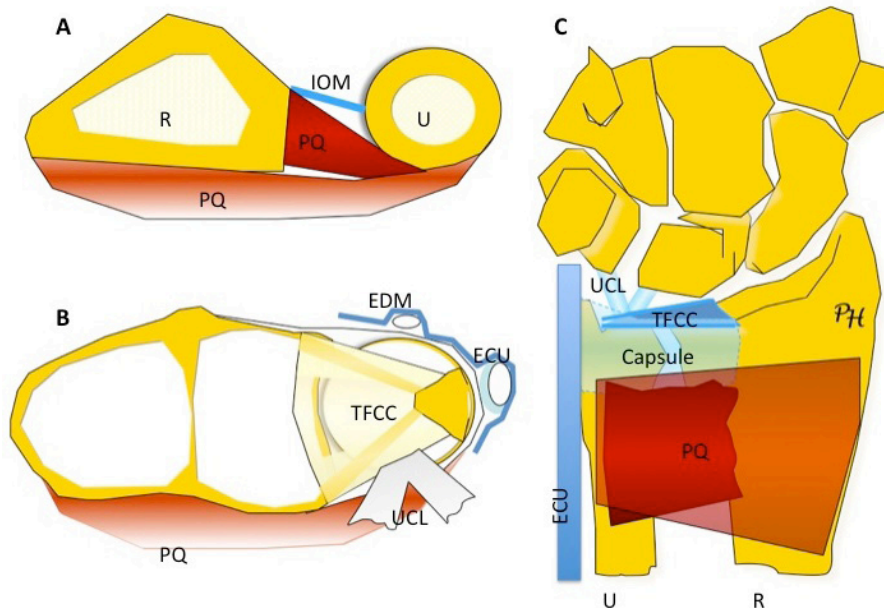
Only a weak level of scientific evidence was found. There were no randomized controlled trials comparing different operative management options and no prospective case series. This review was therefore limited to retrospective studies and case reports.

The identifier 'failed Darrach procedure' traced eight studies published between 1986 and 2010, 'failed Sauvé-Kapandji procedure' traced 13 articles between 1991 and 2011, and 'failed Bower's hemiresection procedure' one article in 1996, whereas there were no results for 'failed matched ulna arthroplasty'. The articles on revision surgery for distal ulna resection procedures can be classified as soft tissue procedures, bone procedures and arthroplasties with implants or other salvage techniques.





**Figure 3:** Anatomic diagram showing the effect of forearm musculature on radio-ulnar impingement. Radio-ulnar convergence is favoured by the contraction of all muscles, except for the brachioradialis. AB: anterior brachial; BR: brachioradialis; PT: pronator teres; PQ: pronator quadratus; APL: abductor pollicis longus.



**Figure 4:** Stabilizers of DRUJ soft tissues. Their distribution avoids radio-ulnar divergence, but no element opposes convergence. R: radius; U: ulna; PQ: pronator quadratus; IOM: interosseus membrane; ECU: extensor carpi ulnaris tendon and sheath; EDM: extensor digiti minimi; TFCC: triangular fibrocartilage complex; UCL: ulno-carpal ligaments.

#### Soft tissue procedures

Soft tissue procedures can be divided between distally-based tenodeses of the ulnar stump and interposition arthroplasties.

Tenodesis has mainly been carried out using the hemi-tendon of flexor

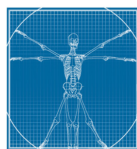
carpi ulnaris (FCU), extensor carpi ulnaris (ECU) or both (Figure 5). The original article to propose stabilization of a failed Darrach procedure with FCU tenodesis was published in 1984 by Tsai and Stilwell<sup>11</sup>. Kessler and Hecht<sup>12</sup> were the first to suggest

using a strip of ECU to stabilize distal ulnar subluxations in rheumatoid patients, applying a similar method to that described for the FCU. There are no detailed reports on the application of ECU tenodesis on the isolation to salvage a painful distal radio-ulnar impingement, but it has been used in primary ulnar head resection to prevent instability. Breen and Jupiter combined distally based FCU with proximally based ECU tenodesis to achieve both static and dynamic stabilization of the distal ulnar stump and obtained good outcomes in three patients<sup>13</sup>.

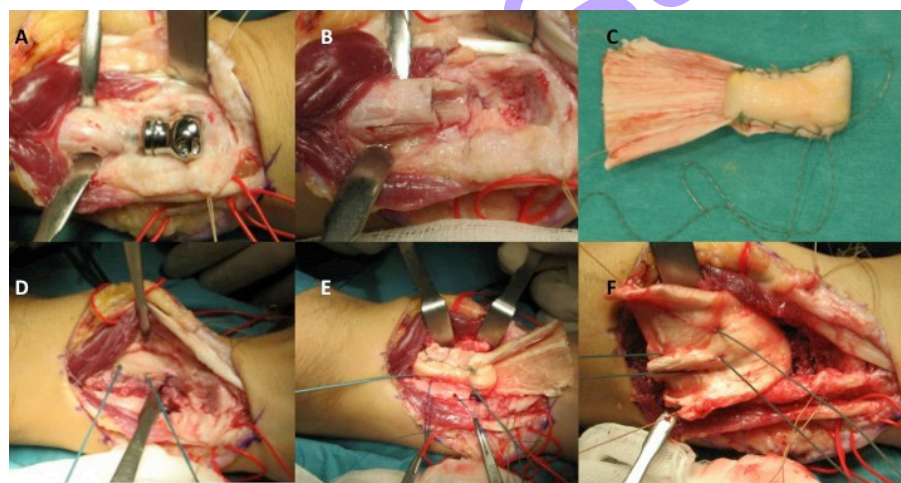
In 1992, Johnson<sup>14</sup> proposed pronator quadratus interposition and, in 2003, Shah and Klimisch<sup>15</sup> reported the interposition and theoretical tenosuspension of the radius by means of tenodesis with the tendon of the brachioradialis. Finally, authors such as Berger and Cooney<sup>16</sup> and Sotereanos<sup>17</sup> recommended interposing an allograft of Achilles' tendon between the radius and ulnar stump (Figure 6). Kleinman and Greenberg<sup>18</sup> applied a combination of soft tissue procedures, stabilizing the distal ulnar stump with a distally based ECU tenodesis and adding a dorsal transfer of the pronator quadratus muscle to interpose a soft tissue cushion between radius and ulna.

#### Bone procedures

Some procedures to palliate instability have focused on the bone segments of the forearm. Although shortening of the unstable ulnar stump is highly controversial, Cooney et al.<sup>19</sup> performed a large number of wide distal ulna resections due to tumours and reported a very low incidence of complications and symptomatic radio-ulnar impingement. Wide ulnar resection has subsequently been applied in patients with failed Darrach's surgery, among other conditions, with apparently good outcomes being reported by Wolfe et al.<sup>20</sup>.



**Figure 5:** Anatomic diagram of ulnar stump stabilization by tenodesis. (a) Most techniques use hemitendon of extensor carpi ulnaris (ECU) or flexor carpi ulnaris (FCU). (b) Tenodesis by the Breen and Jupiter technique. (c) Comparison of the biomechanics of tenodesis with the functioning of a bell. The clapper of the bell represents the ulnar stump and the bell itself the radius. The rope represents the tendons that stabilize the ulnar stump in tenodesis. Tenodesis is ineffective when the bell (radius) moves against the fixed clapper (ulnar stump).



**Figure 6:** Radio-ular interposition arthroplasty with Achilles' tendon allograft. (a) Exposure of painful distal ulna prosthesis. (b) Implant removal. (c) Preparation of Achilles' tendon allograft as a cushion. (d) Placement of two suture anchors on the ulnar side of the radius. (e) Interposition of the allograft between radius and ulna; the allograft is stabilized by the suture anchors. (f) Part of the tendon allograft is used to wrap the ulnar stump.

Based on the assumption of a lower incidence of symptomatic radio-ular convergence with Bower's hemiresections or Watson's matched ulnar resections than with the Darrach and Sauvé-Kapandji techniques, Watson and Brown<sup>21</sup> performed joint levelling by lengthening the ulna to achieve a situation similar to the 'matched ulna', obtaining good results but acknowledging the technical difficulty of the procedure. Ulna lengthening can be conducted by step osteotomy or by tricortical bone grafting<sup>22</sup>.

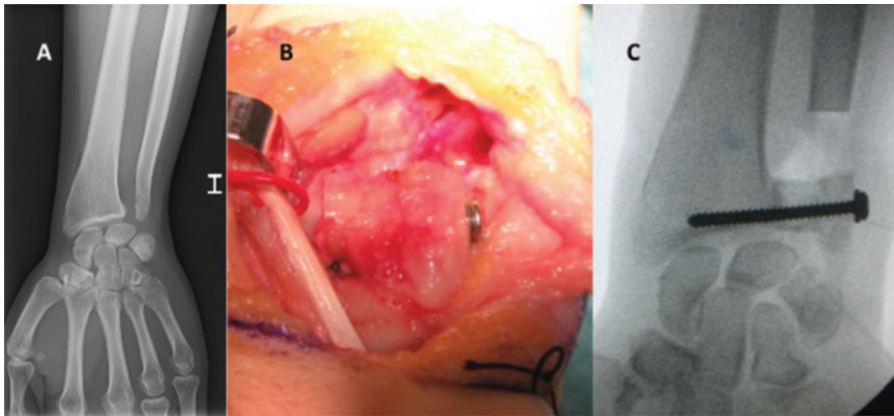
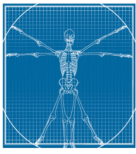
Shortening the radius is conceptually equivalent to lengthening the ulna and is probably responsible for fewer complications, although the only published data is from a study of two patients by García-Elias in 2002, who reported good results<sup>8</sup>. González del Pino and Fernández<sup>23</sup> did not address the biomechanics of radio-ular impingement but proposed a revision technique to convert a painful hemiresection into a Sauvé-Kapandji arthroplasty (Figure 7).

#### Arthroplasties with implant

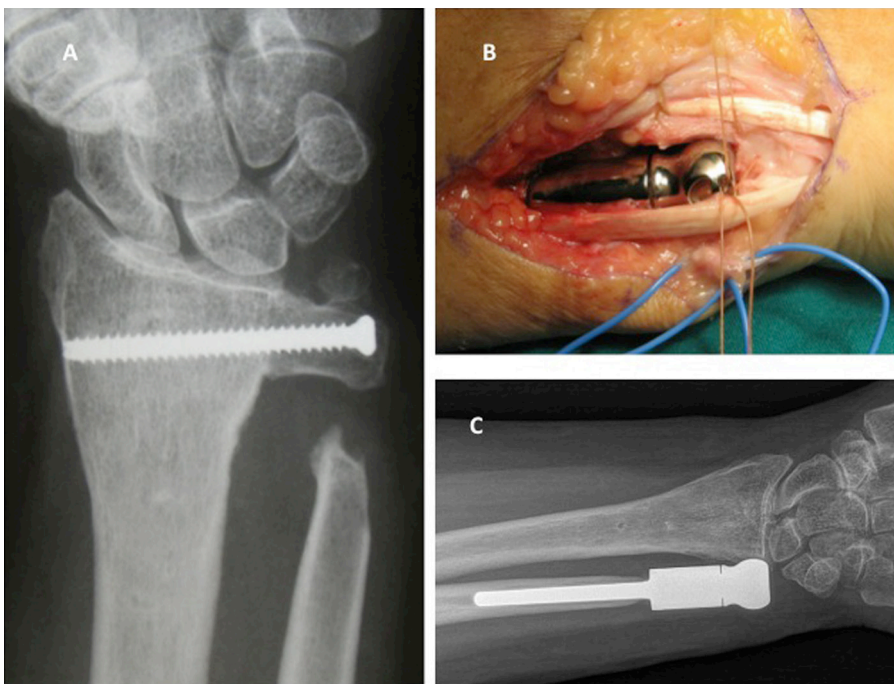
The third DRUJ salvage option is to implant a prosthesis (Figure 8). McMurtry et al.<sup>24</sup> reported on 40 Swanson silicone ulnar head arthroplasties in 37 patients, with a minimum of 12-months follow-up; eight of the procedures were for patients with failed Darrach surgery, but a satisfactory outcome was obtained in only three of these.

The largest sample of failed resection arthroplasty cases was studied by van Schoonhoven et al. in 2000<sup>25</sup>, who used Herbert prostheses (Herbert Ulnar Head Prosthesis, Gebrüder Martin GmbH & Co KG, Tuttlingen, Germany) and reported good pain outcomes, a mean pronosupination of 151° and a 43%–73% improvement in the grip strength of the contralateral hand. A follow-up of the same patients at 12 years<sup>26</sup> found that the good results had persisted and that the implants had not required revision.





**Figure 7:** Conversion of distal ulna hemiresection in Sauvé-Kapandji procedure as suggested by González del Pino. (a) Painful hemiresection arthroplasty. (b) Operative view: A is interposed between the radius and ulnar styloids to favour distal radio-ulnar arthrodesis. The bone defect created leads to proximal ulna pseudoarthrosis. (c) Radiographic view of the procedure.



**Figure 8:** Revision of painful Sauvé-Kapandji by distal ulna prosthesis (Avanta uHead prosthesis; Small Bone Innovations Inc, Morrisville, PA, USA). (a) Radiographic view of Sauvé-Kapandji procedure. (b) Operative view of distal ulna implant. (c) Radiographic appearance of the prosthesis.

In 2006, Fernández et al.<sup>27</sup> proposed a modification of the Herbert prosthesis procedure, using a spherical ulnar head, for the revision of failed Sauvé-Kapandji. It maintains the arthrodesis of the distal ulna, which is given a concave shape to

fit the prosthesis, and they even suggested osteotomy of the distal metaphysis of the radius to fit the implant without removing the fused ulnar head. Willis et al.<sup>28</sup> used an Avanta uHead prosthesis (Small Bone Innovations Inc, Morrisville, PA,

USA) to treat 22 patients with failed distal ulna resection and reported excellent results in 18 of these at 2 years, although there were also 2 cases of aseptic loosening.

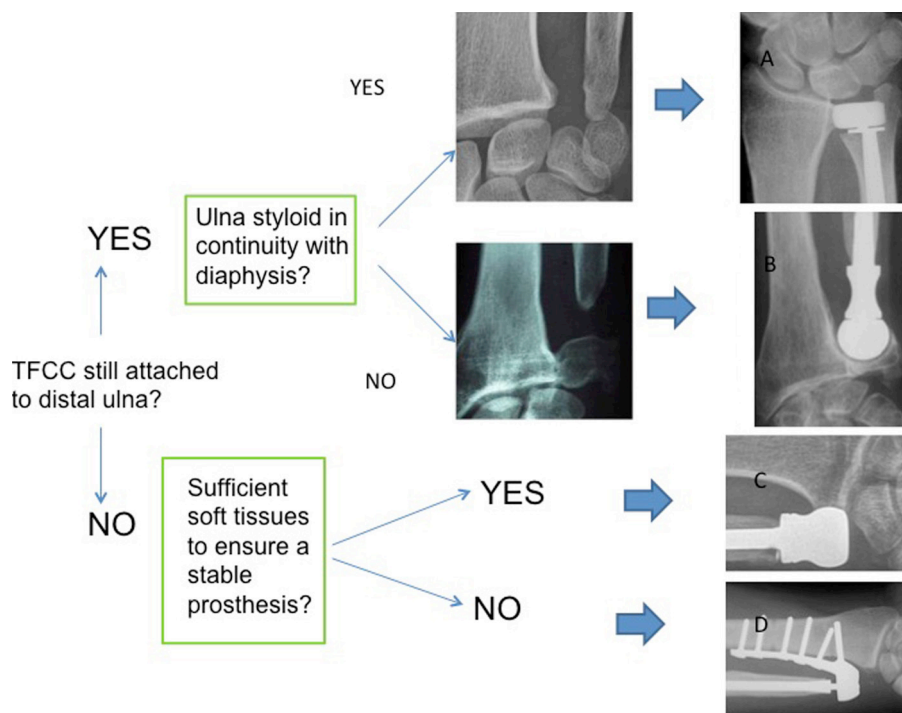
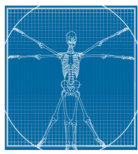
Watts et al.<sup>29</sup> proposed a revision algorithm for using different implants as a function of the soft tissue stabilizers of the DRUJ and the continuity with the styloid process (Figure 9). Total arthroplasty is mandatory when the soft tissues do not guarantee the stability of the distal ulna prosthesis, with the most widely used implant being Scheker's prosthesis<sup>30</sup>.

#### Other salvage techniques

Finally, the creation of a one-bone forearm is presented as the last resort for patients in whom previous techniques have failed. It consists of excision of the distal ulna, followed by osteotomy, transfer and fixing of the radius in slight pronation by means of a plate. This procedure should not be confused with radio-ulnar arthrodesis, although both result in the loss of pronosupination. In a study of 23 patients with tumours and two instabilities due to failed ulnar resection, Peterson et al.<sup>31</sup> reported that less favourable outcomes were associated with traumatic disease and a history of iterative surgical procedures. Allende and Allende<sup>32</sup> described one-bone forearm procedures in seven patients with post-traumatic forearm defects, all of whom evidenced a stable and pain-free forearm at 6 years post-surgery and had returned to their previous occupation.

#### Discussion

Although symptomatic radio-ulnar impingement is relatively frequent after DRUJ resection arthroplasty, no prospective or randomized clinical studies have compared different techniques for its treatment, and there has been only one experimental controlled study<sup>33</sup>. Proposed procedures have been highly varied and are only supported by retrospective



**Figure 9:** Watts' algorithm to indicate the different types of distal ulna prosthesis in the revision of failed resection arthroplasty of the DRUJ. (a) Eclipse™ prosthesis (Bioprofile, Grenoble, France). (b) Herbert's prosthesis (Herbert Ulnar Head Prosthesis, Gebrüder Martin GmbH & Co KG, Tuttlingen, Germany). Fernández's modification of Sauvé-Kapandji revision. (c) Avanta™ uHead prosthesis (Small Bone Innovations Inc, Morrisville, PA, USA). (d) Scheker total prosthesis of the DRUJ (APTIS Medical, Louisville, USA).

studies with small sample sizes and sometimes heterogeneous DRUJ lesions, yielding only level IV evidence and a recommendation grade of C.

More articles have been published on failures with Sauvé-Kapandji and Darrach techniques than on failures with hemiresection and matched Ulna techniques, suggesting that problems may be more frequently associated with complete than the with partial distal ulna resections.

Distal tenodesis techniques have generally been discredited. García-Elias<sup>8</sup> demonstrated the anatomical foundations of the incompetence of these stabilizations as a function of wrist position. All tenodeses remain lax in ulnar deviation of the hand. In a biomechanical study of cadavers, Sauerbier et al.<sup>33</sup> compared the effectiveness of ulna stabilization

after distal resection by tenodesis with ECU and FCU hemitendon, pronator quadratus interposition, or placement of distal ulna prosthesis. They observed that radio-ulnar convergence was not prevented by tenodesis or interposition method after distal ulna resection and that instability may be exacerbated by a pronator quadratus interposition.

The DRUJ can be compared to a bell (Figure 5c). If the clapper moves and hits the bell, it clangs (the wrist hurts). We can stop the movement of the clapper by increasing the tension of the rope holding it (as in tenodesis), but we cannot prevent the clanging if it is the bell (radius) that moves, which is exactly occurs in the wrist.

Interposition of a tendon allograft between the ulna and radius was studied by Sotereanos et al. in 4 patients in 2002<sup>17</sup>, and the same author

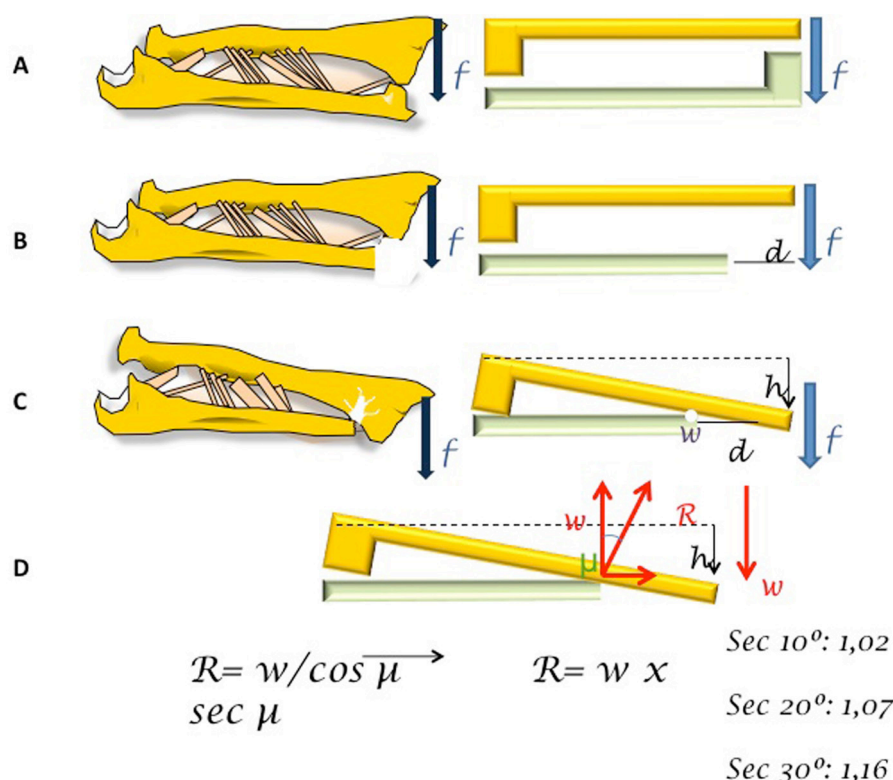
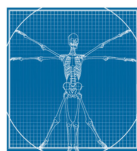
reported a good outcome of this approach in 16 out of 17 patients studied in 2008<sup>34</sup>.

Surgical shortening of the ulnar stump is acknowledged to be irrational and inappropriate as it always results in a new and more proximal impingement, as reported by Bell et al.<sup>2</sup>. Therefore, this procedure is currently in disuse, despite the possibility of obtaining good results from wide resections in tumour disease. Radio-ulnar joint levelling procedures, either by ulnar lengthening or radius shortening, have been described only in case reports or short case series<sup>8,21,22</sup>.

One way of contemplating these treatments is to think of a forearm in which a portion of distal ulna is removed as if it were a grade 3 lever (Figure 10). If  $d$  is the resected length of the ulna, the application of a force ( $f$ ) produces a radio-ulnar convergence with contact at point  $p$ . The momentum of the pair of forces is the product of the force applied by distance  $d$ ; therefore, the momentum increases with a wider ulnar resection. Likewise, in a simple support, the reaction to the application of a weight is always perpendicular to the surface, and the vertical component of the reaction must be equal to the weight borne. The angle of the two vectors increases with ulnar shortening, and the reaction at the point of contact is proportional to the secant of the angle, i.e. the reaction is greater. These mathematical arguments support joint levelling procedures but not iterative shortening of the ulnar stump, consistent with clinical observations.

Nevertheless, wide ulnar resections appear to be better tolerated. One explanation may be that when the arm of the ulnar 'lever' is very short, the radio-ulnar convergence requires a very long downward movement of the radius, probably limited by the soft tissues of the elbow, and there can be no reaction force if there is no point of contact.





**Figure 10:** Comparison of the forearm with a grade 3 lever. (a) Normal forearm. (b and c) Forearm with resection arthroplasty of the distal ulna. If  $d$  is the resected length of the ulna, the application of a force “ $f$ ” determines a radio-ulnar convergence with contact at point  $p$ . The momentum of the pair of forces is the product of the force applied by distance “ $d$ ”; therefore, the momentum increases with wider resection of the ulna. (d) Likewise, in a simple support, the reaction to the application of a weight “ $w$ ” is always perpendicular to the surface, and the vertical component of this reaction must be equal to the weight borne. The angle of the two vectors “ $\mu$ ” increases with the shortening of the ulna, and the reaction at the point of contact is proportional to the secant of the angle, i.e. a greater reaction is produced.

Another possible salvage treatment for failed DRUJ resection arthroplasty is to implant an ulnar head prosthesis, which was found to restore the stability of the DRUJ effectively by simulating the geometry of the ulnar head<sup>33</sup>. However, except for a 12-year follow-up study conducted by van Schoonhoven et al. in 2012<sup>26</sup>, no data are available on the long-term survival of these implants, raising questions about their suitability for younger and higher-demand patients.

Finally, the one-bone forearm procedure is supported by studies of patients who had a different pro-

file<sup>31,32</sup> from that of patients with dynamic radio-ulnar impingement usually encountered in clinical practice. This technique has been associated with a high rate of complications, including a lack of bony union, and the function is markedly reduced by the loss of pronosupination. It is therefore important that patients have realistic expectations of the outcome.

### Conclusion

There is inadequate scientific evidence to recommend a specific treatment for failed DRUJ resection arthroplasty. Distal tenodesis

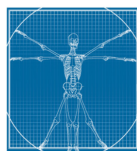
is ineffective. The placement of a partial or total DRUJ prosthesis is the only option that re-establishes the distal pivot point necessary for adequate tensioning of the interosseous membrane, restoring optimal load transfer from the radius to the ulna and vice versa; however, concerns have been raised about its application in young and high-demand patients. Tendon allograft interposition is an alternative to prosthesis substitution.

### Acknowledgement

The authors thank Richard Davies for assistance with the English version.

### References

- Hartz CR, Beckenbaugh RD. Long-term results of resection of the distal ulna for post-traumatic conditions. *J Trauma*. 1979 Apr;19(4):219–26.
- Bell MJ, Hill RJ, McMurtry RY. Ulnar impingement syndrome. *J Bone Joint Surg Br*. 1985 Jan;67(1):126–9.
- McKee MD, Richards RR. Dynamic radio-ulnar convergence after the Darrach procedure. *J Bone Joint Surg Br*. 1996 May;78(3):413–18.
- Dell PC. Distal radio-ulnar dysfunction. *Hand Clin*. 1987 Nov;3(4):563–83.
- Nathan R, Schneider LH. Classification of distal radioulnar joint disorders. *Hand Clin*. 1991 May;7(2):239–47.
- Lees VC, Scheker LR. The radiological demonstration of dynamic ulnar impingement. *J Hand Surg*. 1997;22B:448–50.
- H. Shaaban H, Giakas G, Bolton M, Williams R, Wicks P, Scheker LR, et al. The load-bearing characteristics of the forearm: pattern of axial and bending force transmitted through ulna and radius. *J Hand Surg Br*. 2006 Jun;31(3):274–9.
- García-Elias M. Failed ulnar head resection: prevention and treatment. *J Hand Surg Br*. 2002 Oct;27(5):470–80.
- Bieber EJ, Linscheid RL, Dobyns JH, Beckenbaugh RD. Failed distal ulna resections. *J Hand Surg Am*. 1988 Mar;13(2):193–200.
- García-Elias M. Soft-tissue anatomy and relationship about the distal ulna. *Hand Clin*. 1998 May;14(2):165–76.
- Tsai TM, Stilwell JH. Repair of chronic subluxation of the distal radio-ulnar joint (ulnardorsal) using flexor carpi ulnaris tendon. *J Hand Surg Br*. 1984 Oct;9(3):289–94.



12. Kessler I, Hecht O. Present application of the Darrach procedure. *Clin Orthop Relat Res.* 1970 Sep-Oct;72:254-60.
13. Breen TF, Jupiter JB. Extensor carpi ulnaris and flexor carpi ulnaris tenodesis of the unstable distal ulna. *J Hand Surg Am.* 1989 Jul;14(4):612-7.
14. Johnson RK. Stabilization of the distal ulna by transfer of the pronator quadratus origin. *Clin Orthop Relat Res.* 1992 Feb;275:130-2.
15. Shah M, Klimisch J. Treatment of failed Darrach procedure including the brachioradialis sling. *Curr Opin Orthop.* 2003;14:222.
16. Berger RA, Cooney WP 3rd. Use of an ulnar head endoprosthesis for treatment of an unstable distal ulnar resection: review of mechanics, indications, and surgical technique. *Hand Clin.* 2005 Nov;21(4):603-20.
17. Sotereanos DG, Göbel F, Vardakas DG, Sarris I. An allograft salvage technique for failure of the Darrach procedure: a report of four cases. *J Hand Surg Br.* 2002 Aug;27(4):317-21.
18. Kleinman WB, Greenberg J. Salvage of failed Darrach procedure. *J Hand Surg Am.* 1995 Nov;20(6):951-8.
19. Cooney WP, Damron TA, Sim FH, Linscheid RL. En bloc resection of tumors of the distal end of the ulna. *J Bone Joint Surg Am.* 1997 Mar;79(3):406-12.
20. Wolfe SW, Mih AD, Hotchkiss RN, Culp RW, Kiefhaber TR, Nagle DJ. Wide excision of the distal ulna: a multicenter case study. *J Hand Surg Am.* 1998 Mar;23(2):222-8.
21. Watson HK, Brown RE. Ulnar impingement syndrome after Darrach procedure: treatment by advancement lengthening osteotomy of the ulna. *J Hand Surg Am.* 1989 Mar;14(2 Pt 1):302-6.
22. Ross M, Thomas J, Couzens G, Coleman S. Salvage of the unstable Sauvé-Kapandji procedure: a new technique. *Tech Hand Up Extrem Surg.* 2007 Mar;11(1):87-92.
23. González del Pino J, Fernández DL. Salvage procedure for failed Bower's hemiresection interposition technique in the distal radioulnar joint. *J Hand Surg Br.* 1998 Dec;23(6):749-53.
24. McMurtry RY, Paley D, Marks P, Axelrod T. A critical analysis of Swanson ulnar head replacement arthroplasty: rheumatoid versus nonrheumatoid. *J Hand Surg Am.* 1990 Mar;15(2):224-31.
25. van Schoonhoven J, Fernandez DL, Bowers WH, Herbert TJ. Salvage of failed resection arthroplasties of the distal radioulnar joint using a new ulnar head prosthesis. *J Hand Surg Am.* 2000 May;25(3):438-46.
26. van Schoonhoven J, Mühlendorfer-Fodor M, Fernandez DL, Herbert TJ. Salvage of failed resection arthroplasties of the distal radioulnar joint using an ulnar head prosthesis: long-term results. *J Hand Surg Am.* 2012 Jul;37(7):1372-80.
27. Fernández DL, Joneschild ES, Abella DM. Treatment of failed Sauvé-Kapandji procedures with a spherical ulnar head prosthesis. *Clin Orthop Relat Res.* 2006 Apr;445:100-7.
28. Willis AA, Berger RA, Cooney WP 3rd. Arthroplasty of the distal radioulnar joint using a new ulnar head endoprosthesis: preliminary report. *J Hand Surg Am.* 2007 Feb;32(2):177-89.
29. Watts AC, Hayton MJ, Stanley JK. Salvage of failed distal radioulnar joint reconstruction. *Hand Clin.* 2010 Nov;26(4):529-41.
30. Schecker LR, Babb BA, Killion PE. Distal ulnar prosthetic replacement. *Orthop Clin North Am.* 2001 Apr;32:365-76.
31. Peterson CA 2nd, Maki S, Wood MB. Clinical results of the one-bone forearm. *J Hand Surg Am.* 1995 Jul;20(4):609-18.
32. Allende C, Allende BT. Posttraumatic one-bone forearm reconstruction. A report of seven cases. *J Bone Joint Surg Am.* 2004 Feb;86-A(2):364-9.
33. Sauerbier M, Hahn ME, Berglund LJ, An KN, Berger RA. Biomechanical evaluation of the dynamic radioulnar convergence after ulnar head resection, two soft tissue stabilization methods of the distal ulna and ulnar head prosthesis implantation. *Arch Orthop Trauma Surg.* 2011 Jan;131(1):15-26.
34. Greenberg JA, Sotereanos D. Achilles allograft interposition for failed Darrach distal ulna resections. *Tech Hand Up Extrem Surg.* 2008 Jun;12(2):121-5.